

Erwin J.O. Kompanje¹ & Peter S.J. Klaver²¹Natuurmuseum Rotterdam²Natura Artis Magistra

A possible case of diffuse idiopathic skeletal hyperostosis (DISH, Ankylosing hyperostosis) in an orang-utan *Pongo pygmaeus pygmaeus* (Linnaeus, 1760)

Kompanje, E.J.O., & Klaver, P.S.J., 1995 - A possible case of diffuse idiopathic skeletal hyperostosis (DISH, ankylosing hyperostosis) in an orang-utan *Pongo pygmaeus pygmaeus* (Linnaeus, 1760) - DEINSEA 2: 17-21 [ISSN 0923-9308]. Published 30 November 1995.

In this article the skeleton of a 42 year old Bornean orang-utan *Pongo pygmaeus pygmaeus* (Linnaeus, 1760) is discussed. The typical pathological changes of the thoracic vertebrae are most consistent with diffuse idiopathic skeletal hyperostosis (DISH). This disease is well known in man, but to our knowledge this report is the first description of a possible case of DISH in another mammal.

Een mogelijk geval van diffuse idiopathic skeletal hyperostosis (DISH, ankylosing hyperostosis) bij een orang-oetan Pongo pygmaeus pygmaeus (Linnaeus, 1760) - In dit artikel wordt het skelet van een 42 jarige orang-oetan *Pongo pygmaeus pygmaeus* (Linnaeus, 1760) besproken. De typische afwijkingen aan de thoracale wervels komen het meest overeen met de afwijkingen diagnostisch voor DISH (diffuse idiopathic skeletal hyperostosis). Deze ziekte is bekend bij mensen, maar volgens ons nog niet eerder bij een ander zoogdier beschreven.

Correspondence: Erwin J.O. Kompanje, Natuurmuseum Rotterdam, P.O. Box 23452, NL-3001 KL Rotterdam, the Netherlands; Peter S.J. Klaver, Natura Artis Magistra, Plantage Kerklaan 40, NL-1018 CZ Amsterdam, the Netherlands.

Keywords: orang-utan, *Pongo pygmaeus pygmaeus*, vertebral pathology, ankylosing, hyperostosis, DISH.

INTRODUCTION

On 27 January 1992, a male orang-utan *Pongo pygmaeus pygmaeus* (Linnaeus, 1760), named 'Sam', died of old age in the zoological gardens (Natura Artis Magistra) of Amsterdam, the Netherlands. The animal was born in 1950 on Borneo, Indonesia, and arrived in the Netherlands on 12 December 1952. The skin and skeleton of the deceased animal were prepared at the Zoological Museum, University of Amsterdam, the Netherlands (ZMA 24.488). Forty-two

years is extremely old for a Bornean orang-utan (Becker 1991; 1993).

The skeleton showed typical hyperostosis and calcification on the right side of the thoracic vertebrae, consistent with the skeletal disease known in human pathology under the name of Diffuse Idiopathic Skeletal Hyperostosis (DISH, ankylosing hyperostosis). In this article, the features of this case are described and the disease is discussed.

DISH

Diffuse Idiopathic Skeletal Hyperostosis (DISH) or ankylosing hyperostosis is a common skeletal disease of unknown etiology in man. Features consistent with DISH have been described in literature under different names (Table 1). The disease occurs after middle age, and more often in males than in females. The principal manifestations are ligamentous calcification and ossification of the anterolateral (antiacardiac) part of the spinal column, sometimes leading to ankylosis. The appearance of the osteophytes has been described as 'dripping candle wax', involving three or four vertebral bodies. DISH is distinguished from ordinary spondylosis deformans by the absence of disc degeneration. The distal thoracic spine is the part of predilection. There is, in contrast with spondylosis deformans, an absence of erosions and sclerosis of the vertebral epiphysis.

Table 1. Synonyms for DISH

- Moniliform hyperostosis (Meyer & Forestier 1938)
- Spondylitis ossificans ligamentosa (Oppenheimer 1942)
- Senile ankylosing hyperostosis of the spine (Forestier & Rotes-Querol 1950)
- Ankylosing hyperostosis (Harris et al. 1974)
- Hyperostosis of the spine (Forestier & Lagier 1971)
- Diffuse idiopathic skeletal hyperostosis (Resnick, Shaul & Robins 1975)

The appearance of the vertebral pathology has often led to confusion with ankylosing spondylitis and with spondylosis deformans. DISH and spondylosis deformans are often found together in one individual. In some cases there may be extraspinal manifestations in the form of bony spurs around the patellae, olecranon and calcaneus (Utsinger 1984; Quinet & Hadler 1988). In humans this is about 35 % (Utsinger 1984). Patients often complain about dysphagia due to compression of the oesophagus by the osteophytes. The compression is severe enough to make eating solid food a strenuous chore. Hyperglycaemia may occur and the incidence of diabetes mellitus is about 40 %. The therapy for DISH is symptomatic.

As the name already indicates, the etiology and pathogenesis of DISH is unknown. Research so far has focused on possible metabolic-endocrine and toxic factors. The relation between diabetes mellitus and DISH may provide some insight. Diabetes is mysteriously associated with rheumatic conditions with proliferation of fibrous tissue (Dwosh 1983).

PATHOLOGICAL CHANGES IN THE DESCRIBED CASE

Autopsy on the dead *Pongo* was performed one day after death. A mild splenomegaly and some chronic ulcerations in the colon were found. Some mesenteric lymph-nodes were enlarged, having a purulent content. The intriguing pathology of the vertebrae became visible after cleaning the skeleton by maceration. The atlas shows a small osteophyte on the inner side of the lateral mass. The second cervical vertebra shows severe pathology (Fig. 1). The left inferior articular process shows severe macroscopic bone changes. The whole area of contact is covered with perforations and there are marginal osteophytes.

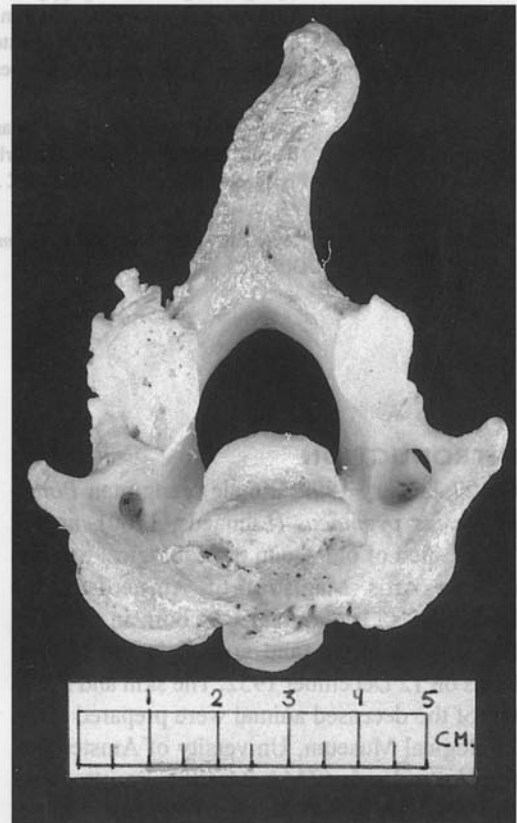

Figure 1 *Pongo pygmaeus pygmaeus* (ZMA 24488), second cervical vertebra; note the severe macroscopic bone changes on the left inferior articular process.

[photogr. Rob 't Hart]

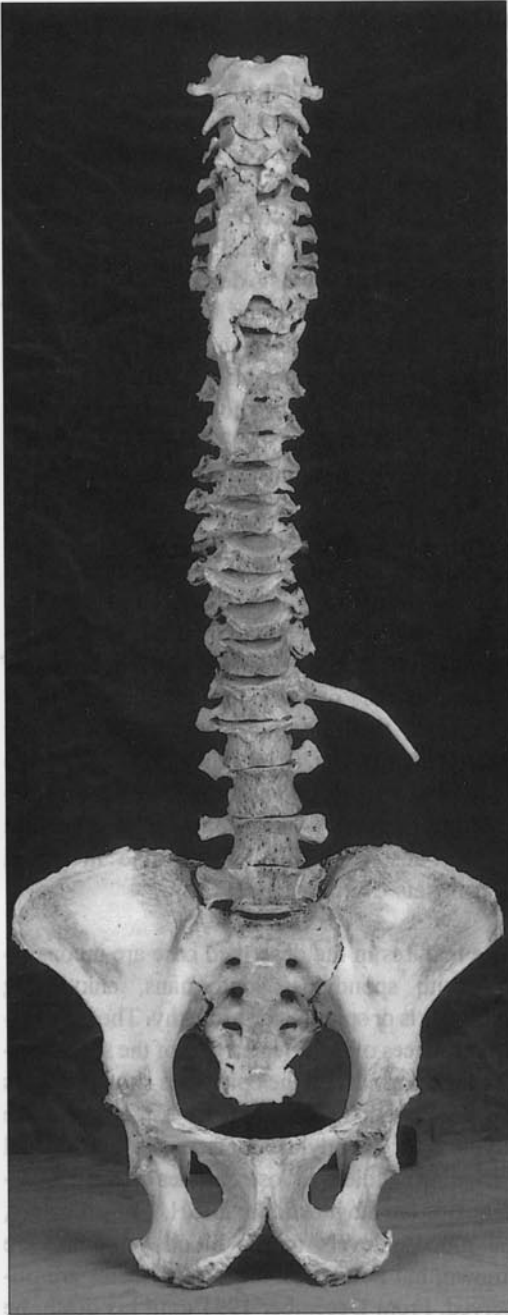


Figure 2 *Pongo pygmaeus pygmaeus* (ZMA 24488), mounted vertebral column and pelvis; the typical 'dripping candle wax' osteophytes are clearly visible.

The spinous process is curved to the right. The body of this vertebra also shows pathological changes with marginal osteophytes. These features are consistent with cervical spondylosis

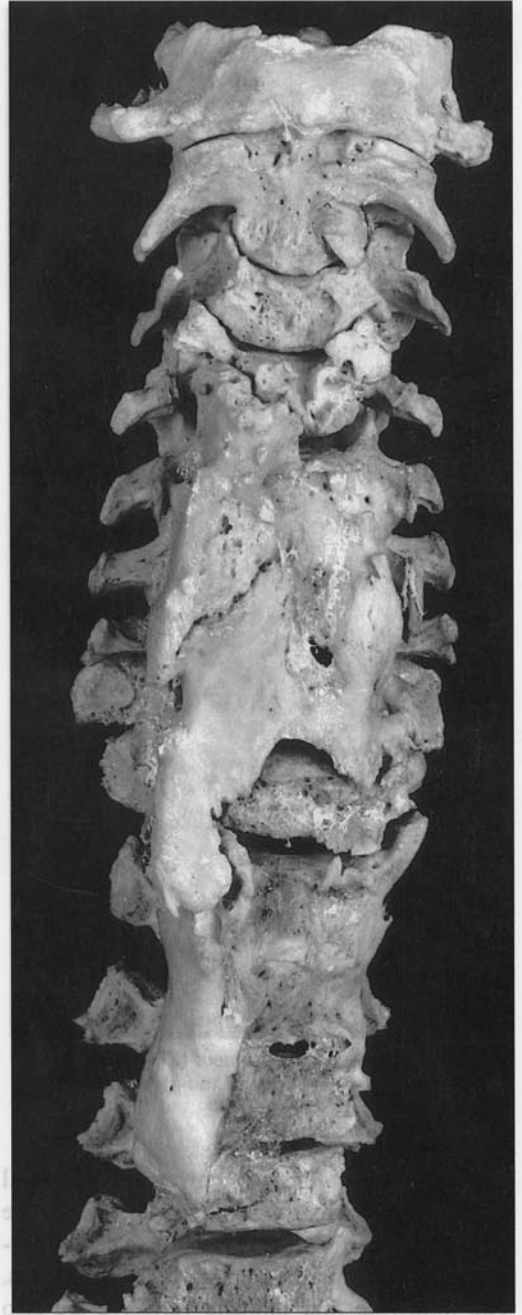


Figure 3 *Pongo pygmaeus pygmaeus* (ZMA 24488), detail of the cervical and upper thoracic vertebrae. [both photographs: Rob 't Hart]

deformans. The third and fourth cervical vertebra also shown marginal osteophytes. The following three cervical vertebrae (5-7) are fused together by grotesque new bone formation (Figs. 2, 3 & 4).

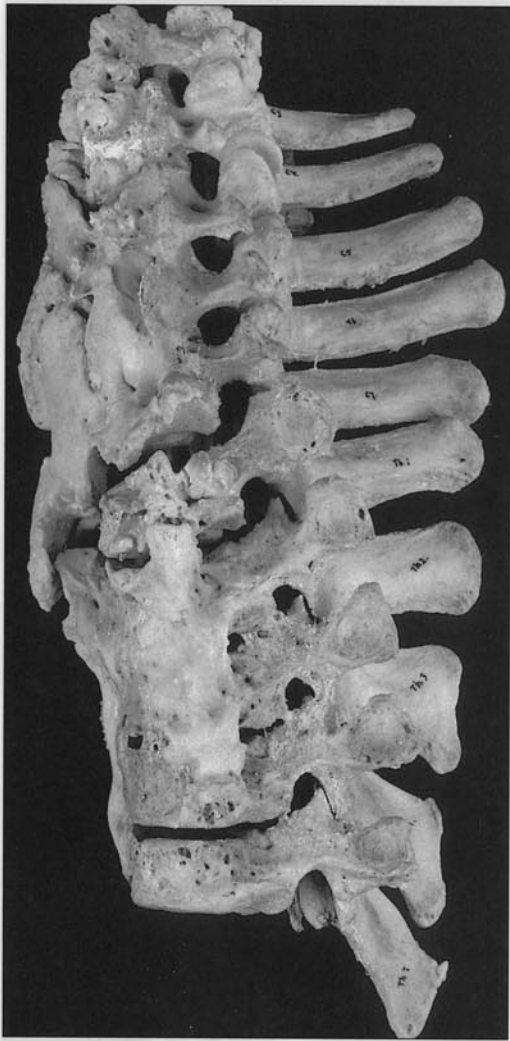

Figure 4 *Pongo pygmaeus pygmaeus* (ZMA 24488), lateral view of the third cervical to fifth thoracic vertebra. [photogr. Rob 't Hart]

The intervertebral spaces, however, are normal and show no perforations and/or sclerosis of the epiphysis. The first thoracic vertebra shows normal epiphysis, but severe marginal osteophytes. The following four thoracic vertebrae are also fused together by a grotesque ankylosis. Again, the intervertebral spaces and epiphyses are normal. The following thoracic and lumbar vertebrae show only degenerative changes consistent with the age of the animal. The other extraspinal bones of the skeleton and the skull show no gross pathology. The teeth are worn and the jaws show the results of periodontitis, which is normal for a primate that lived in a zoo for several years.

DISCUSSION

Ottow (1951) studied several skeletons of gorilla *Gorilla gorilla*, chimpanzee *Pan troglodytes* and orang-utan. Traces of spondylosis deformans were found in none of the 22 skeletons of orang-utan. Ottow (1951) cited Fox (1939), who studied 41 skeletons of orang-utan, two of which showed skeletal deformations consistent with spondylosis deformans. Clevenger et al. (1971) speculate on the possible role of *Mycoplasma* infections in the genitourinary and upper respiratory tract, and its possible role in the etiology of rheumatoid arthritis in primates. Hime et al. (1972) described a case of hypertrophic pulmonary osteoarthropathy in an 14 year old orang utan. Adams et al. (1987) described a case of ankylosing spondylitis in a 30 year old female gorilla *Gorilla gorilla*. Rothschild & Woods (1989) studied ninety-nine skeletons of adult lowland gorillas *Gorilla g. gorilla* for the evidence of monoarticular or osseous pathology. In 8 skeletons they found moderate to severe osteoarthritis. In 20 individuals (17 and 3) they found sacroiliac and reactive erosive pathology (spondyloarthropathy). Rothschild (1993) described this feature also in tufted marmosets *Callitrix jacchus*.

The features in the described case are inconsistent with spondylosis deformans, ankylosing spondylitis or spondyloarthropathy. The intervertebral spaces of the affected part of the spinal column are normal and the epiphyses show no signs of degeneration. The bizarre osteophytes are atypical for spondylosis deformans. The typical 'dripping candle wax' osteophytes on the anticardiac side are diagnostic for DISH. Unfortunately, no glucose levels in the blood of 'Sam' are known, but no clinical signs of diabetes are observed. From December 1991 until his death, he ate only soft food. This could be due to the dysphagia which is diagnostic for DISH in humans. The last 6 years of his life 'Sam' showed stiffness, especially in winter time. Almost forty percent of human patients with DISH are complaining about stiffness aggravated by cold and wet weather (Utsinger 1984).

We are not aware of any case of DISH in a mammal other than man.

ACKNOWLEDGEMENTS

We would like to thank Dr. Peter J.H. van Bree (Zoological Museum, University of Amsterdam) for bringing this interesting case to the attention of the first author and for lending some skeletons of orang-utan for comparison. We are indebted to Mr. Rob 't Hart who made the photographs.

REFERENCES

Adams, R.F., Flinn, G.S. & Douglas, M., 1987 - Ankylosing spondylitis in a nonhuman primate: A monkey tail - *Arthritis and Rheumatology* 30: 956-957

Becker, C., 1991 - Orang-Utans - Europäisches Erhaltungszuchtprogramm Zuchtbuch für Kontinental-Europa X/1991

Becker, C., 1993 - Orang-utan (*Pongo pygmaeus spp.*) - EEP Annual Report 1993

Clevenger, A.B., Marsh, W.L. & Peery, T.M., 1971 - Clinical laboratory studies of the gorilla, chimpanzee, and orang-utan - *American Journal of Clinical Pathology* 55: 479-488

Dwosh, I.L., 1983 - Diffuse idiopathic skeletal hyperostosis. Degenerative disease or metabolic disturbance - *Journal of Rheumatology (Suppl.)* 9: 101-102

Forestier, J. & Rotes-Querol, J., 1950 - Senile ankylosing hyperostosis of the spine - *Annals of the rheumatic diseases* 9: 321-330

Forestier, J. & Lagier, R., 1971 - Ankylosing hyperostosis of the spine - *Clinical Orthopedics* 74: 65-83

Fox, H., 1938 - Chronic arthritis in wild mammals - *Transactions of the American Philosophical Society* 8: 74-123

Harris, J. Carter, A., Glick, E. & Storey, G., 1974 - Ankylosing hyperostosis: clinical and radiological features - *Annals of Rheumatic diseases* 33: 210-215

Hime, J.M., Keymer, I.F. & Appleby, E.C., 1972 - Hypertrophic pulmonary osteoarthropathy in an orang-utan (*Pongo pygmaeus*) - *Veterinary Record* 91: 334-337

Meyer, M. & Forster, E., 1938 - Considérations pathogéniques sur l'hyperostose moniliforme du flanc froit de la colonne dorsale - *Revue Rhumatisme et des maladies osteo-articulaires* 5: 286-293

Oppenheimer, A., 1942 - Calcification and ossification of vertebral ligaments (spondylitis ossificans ligamentosa) - *Radiology* 38: 160-164

Ottow, B., 1951 - Spondylitis deformans bei Antropoiden, namentlich dem Gorilla - *Zeitschrift für Morphologie und Anthropologie* 63: 206-221

Quinet, R.J. & Hadler, N.M., 1988 - Mechanical problems of the dorsolumbar spine - In: Katz, W.A. (Ed.) - *Diagnosis and management of rheumatic diseases* - J.B. Lippincott Company, Philadelphia

Resnick, D., Shaul, S. & Robins, J., 1975 - Diffuse idiopathic hyperostosis (DISH): Forestier's disease with extraspinal manifestations - *Radiology* 115: 513-524

Rothschild, B.M., & Woods, R.J., 1989 - Spondyloarthropathy in Gorillas - *Seminars in Arthritis and Rheumatism* 18: 267-276

Rothschild, B.M., 1993 - Arthritis of the spondyloarthropathy variety in *Callitrix jacchus* - *Journal of Medical Primatology* 22: 313-316

Utsinger, P.D., 1984 - Diffuse idiopathic skeletal hyperostosis (DISH, Ankylosing hyperostosis) - In: Moskowitz, R.W. et al. (Eds.) - *Osteoarthritis, diagnosis and management* - W.B. Saunders Company, Philadelphia: 225-233

received 14 February 1995
accepted 17 March 1995